



PATIENT

Willow Dickerson

SPECIES

Canine

BREED

Maltipoo

SEX

FI

AGE

2

WEIGHT

10.2lb

INTERPRETED BY

R. McKenzie Daniel,
DVM, DABVP
(Canine and Feline)

IMAGING PERFORMED BY

Juli Sorenson

HOSPITAL NAME

Emergency
Veterinarians of Idaho

REFERRING VET

Juli Sorenson

INVOICE

24935

DATE

05/26/2026

PRESENTING CLINICAL SIGNS

24 hour history of vomiting, diarrhea, anorexia.

Abnormal PE/Chem/CBC/UA Results: Mild neutrophilia 14k, Rads show colitis. Pancreatic lipase normal. Abdomen fairly tense.

ULTRASONOGRAPHIC EXAMINATION OF THE ABDOMEN

Urinary System

The urinary bladder, trigone, cystourethral junction, and visible pelvic urethra to a depth of 3 cm exhibited normal thickness and tone. Anechoic urine was present in the lumen with no evidence of urine/lumen sediment, mineral, or calculi. The ureteral papillae were normal. The ureters were not visible which is normal. No evidence of inflammatory or neoplastic changes was noted.

No obvious pathology in the area of the uterus or bilateral ovaries.

Normal size and margination were present in the kidneys. A normal 1:3 cortex / medulla ratio and normal corticomedullary definition were maintained. The echogenicity of the cortex was similar to or slightly less than normal liver parenchyma while the medulla echogenicity was hypoechoic to the cortex with no evidence of pelvic dilation. The left kidney measured 3.4 cm in length. The right kidney measured 3.8 cm in length.

The area of the aortic trifurcation was free of pathology.

Adrenal Glands

The left adrenal gland was uniform in size and contour with a uniformly hypoechoic parenchyma. The left adrenal gland measured 0.42 cm width at the caudal pole. The right adrenal gland was uniform in size and contour with a uniformly hypoechoic parenchyma. The right adrenal gland measured 0.46 cm width at the caudal pole.

Spleen

The spleen exhibited a finely textured and homogenous parenchyma which was hyperechoic to the liver and renal cortical parenchyma. The capsule was smooth and regular without apparent expansion. The splenic vasculature at the hilus was normal in volume with no evidence of congestion or thrombosis. Acute to chronic inflammatory, neoplastic, or benign parenchyma changes were not noted.

Liver/Gallbladder

The liver was subjectively normal in size, structure, and contour. The liver parenchyma was uniform and hypoechoic to the spleen with a mild coarse echotexture. Normal vascular volume. The hepatic and portal vasculature were normal in appearance without signs of congestion. The gallbladder was non-distended in size with thin walls and primarily anechoic luminal content. The cystic and common bile ducts were normal.

Gastrointestinal

The stomach presented intact mildly prominent wall layering with mild retained non-shadowing chyme. No evidence of gastric foreign material or obstruction to pyloric outflow.



PATIENT

Willow Dickerson

SPECIES

Canine

BREED

Maltipoo

SEX

FI

AGE

2

WEIGHT

10.2lb

The small intestine presented intact wall layering with 1:3 muscularis/mucosa ratio. The lumen of the small intestine was empty with no signs of mechanical/metabolic ileus, obstruction or foreign material.

The colon walls presented intact yet mild thickened wall layering. Soft fecal matter consistent with patient history and lumen gas was present in the non-distended colon.

Pancreas

The left pancreas was normal in size /contour. Mild non-homogenous parenchyma compared to adjacent non-reactive or inflamed omentum was present.

Free Abdomen

No evidence of peritoneal effusion was present.

Intermittent mildly prominent to enlarged jejunocolic lymph nodes were present. The lymph nodes were essentially isoechoic to adjacent omentum without evidence of peripheral inflammation and maintaining a normal width: length ratio (<0.5).

ULTRASONOGRAPHIC FINDINGS

Primary

- Non-specific gastroenterocolitis
- Mildly non-homogenous pancreas
- Intermittent mild jejunocolic lymphadenopathy - consistent with benign criteria i.e. mild reactive hyperplasia or possible lymphadenitis

INTERPRETATION OF THE FINDINGS & FURTHER RECOMMENDATIONS

No evidence of mechanical gastrointestinal obstructive pattern, foreign material or mural pathology such as intussusception. The appearance of the gastrointestinal tract is non-specific with considerations including dietary intolerance / food hypersensitivity, infectious disease, dysbiosis, enterotoxin, inflammatory bowel disease, mild pancreatitis, occult parasitism, occult Addison's Disease, or other.

Empirically, a limited antigen or hydrolyzed diet trial with potential long term dietary therapy, prophylactic deworming (Panacur 50 mg/kg SID x 5 consecutive days with repeat protocol in 3 weeks even if fecal testing is negative), high colony count probiotic (Provable or Visbiome), cobalamin supplementation pending assessment of cobalamin level +/- antibiotic trial with consideration for adverse effects on normal GI flora with long term antibiotic use and as needed gastrointestinal support with assessment of clinical response may prove beneficial. Intestinal biopsies may be indicated if GI signs continue despite empirical therapy.

A GI panel to include PLI/TLI/Cobalamin/Folate, fresh fecal analysis to assess for parasitic ova / Giardia and resting cortisol is warranted.

INTERPRETED BY

R. McKenzie Daniel,
DVM, DABVP
(Canine and Feline)

IMAGING PERFORMED BY

Juli Sorenson

HOSPITAL NAME

Emergency
Veterinarians of Idaho

REFERRING VET

Juli Sorenson

INVOICE

24935

DATE

05/26/2026



PATIENT

Willow Dickerson

SPECIES

Canine

BREED

Maltipoo

SEX

FI

AGE

2

WEIGHT

10.2lb

INTERPRETED BY

R. McKenzie Daniel,
DVM, DABVP
(Canine and Feline)

IMAGING PERFORMED BY

Juli Sorenson

HOSPITAL NAME

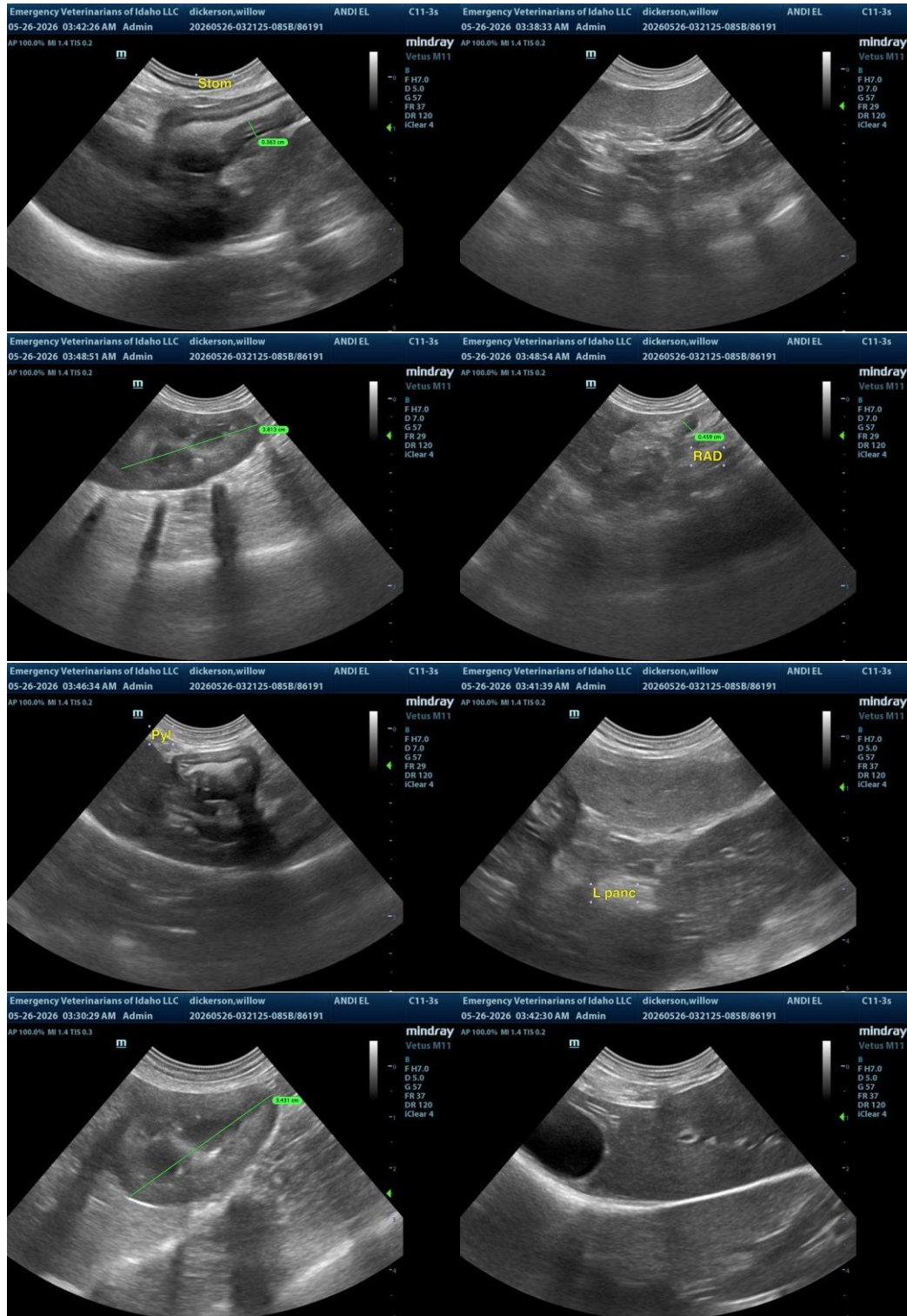
Emergency
Veterinarians of Idaho

REFERRING VET

Juli Sorenson

INVOICE
24935

DATE
05/26/2026





PATIENT

Willow Dickerson

SPECIES

Canine

BREED

Maltipoo

SEX

FI

AGE

2

WEIGHT

10.2lb

INTERPRETED BY

R. McKenzie Daniel,
DVM, DABVP
(Canine and Feline)

IMAGING PERFORMED BY

Juli Sorenson

HOSPITAL NAME

Emergency Veterinarians of Idaho

REFERRING VET

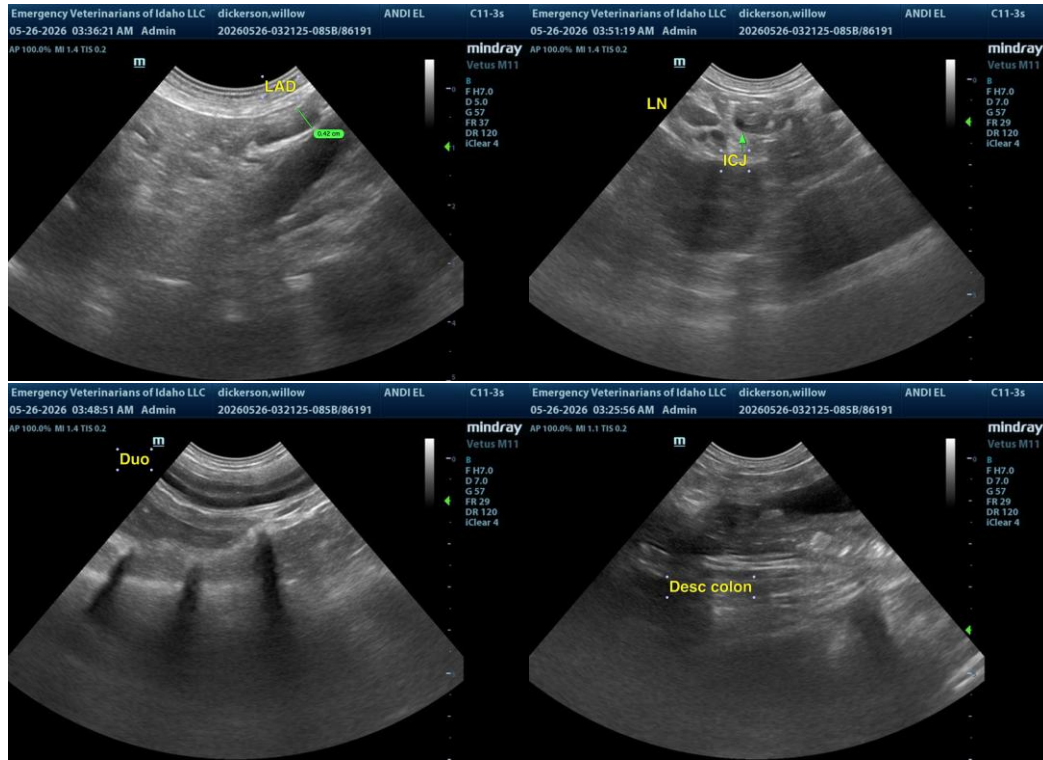
Juli Sorenson

INVOICE

24935

DATE

05/26/2026



The information and recommendations provided are based on the images presented by the referring veterinarian/sonographer. No evaluation can be communicated regarding pathology that was not visible in the image/video clips provided.

Thank you for this referral. If the clinical or image interpretation does not parallel your findings or if I can be of any further assistance, please contact me.

R. McKenzie Daniel, DVM, DABVP (Canine/Feline Practice)
info@sonopath.com